



**PATIENT**

Blackie Trionfetti

**SPECIES**

Feline

**BREED**

DSH

**SEX**

Female Spayed

**AGE**

9 years

**WEIGHT**

12lbs

**INTERPRETED BY**

Maggie Machen Lamy,  
DVM, DACVIM  
(Cardiology)

**IMAGING PERFORMED BY**

Renee Trionfetti, VMD

**HOSPITAL NAME**

Blue Pearl Wyomissing

**REFERRING VET**

Dr. Trionfetti

**INVOICE**

45629

**DATE**

11/3/25

**PRESENTING CLINICAL SIGNS**

History: New grade 2-3/6 heart murmur. Outdoor cat that suffered a significant unknown blunt force trauma (kick by horse vs fall from tree vs other). Trauma resulted in pneumothorax (thoracocentesis preformed, 25mls air removed), pulmonary contusions, right sided herniation of small intestines through a large rent in the right lateral abdominal wall, R&A of approx 4 inches distal jejunum. No external wounds/injuries aside from ecchymosis on the abdomen. No rib fractures or appendicular fractures. Day 2: murmur not appreciated but is purring consistently. Hosp: O2 cage, IVF, Enrofloxacin IV, Gabapentin PO, Methadone IV - > changed to Buprenorphine IV, Ondansetron.

-Abnormal PE/Chem/CBC/UA Results: BPs throughout Hospitalization: 126, 115, 122 mmHg - CBC: WBC 22.69 (H), Neut 19.18 (H), suspected bands, Eos 0.01 (L) - Chem: Glu 171 (H), Crea 0.3 (L), BUN 37 (H), K 3.2 (L), ALT 692 (H) - EPOC: pH 7.362, K 3.5 (L), iCa 1.1 (L), Cl 127, Na 157, HCT 33%, Glu 202 (H), Lac 3.05, BUN 33 (H), Crea 0.53 (L).

-Whole body radiographs pre-op: no obvious fractures are noted. body wall hernia with intestines entrapped • Whole body radiographs post-op: pneumothorax, no obvious pulmonary contusions are noted - Recheck lateral CXR Day 2: Suspected few areas on pulmonary contusions. No pulmonary edema. - TFAST: > 5 B-lines caudal dorsal, left.

**ECHOCARDIOGRAM FINDINGS**

2D, m-mode, color flow and doppler imaging is available. The left ventricular wall is normal in dimension. There is a mildly hyperechoic endocardium consistent with fibrosis. Mild remodeling. The papillary muscles are hyperechoic yet normal in size. The left atrium is normal in size. The right atrium is normal in size. The right ventricle appears normal. The mitral valve is normal in structure and mobility. No MR or SAM identified. The tricuspid valve appears normal in structure and mobility. No TR. Blood flow through both the LVOT and RVOT are normal in velocity. No AI/PI seen. No effusions. No obvious cardiac tumors.

**CARDIAC CHART**

FELINE CARDIAC PARAMETERS	BODY WEIGHT (kg)	HR (BPM)	IVSd (cm) (Moise, Pipers)	LVIDd (cm) (Moise, Pipers)	LVWd (cm) (Moise, Pipers)	FS (%)	EF (%)
NORMAL PARAMETER	-----	150-240	0.35-0.55	<2 (mean 1.5)	3.5-0.55	35-67	80-100
PATIENT	5.4	240	0.47	1.4	0.47	48	90
FELINE CARDIAC PARAMETERS	LA/AO (Boon)	LA/AO HEART BASE (Swe) (Abbott)	LA 2D short axis Base view (cm) (Abbott)		LVOT VEL (m/s)	RVOT VEL (m/s)	E max (m/s)
NORMAL	<1.5	<1.3	<1.2		<1.6	<1.3	<0.9
PATIENT	NM	1.2	1.1		1.2	1.2	NM

*\*Note: All measurements based upon multi-modal images and methods. An average value is reported.  
Adapted from June Boon, Veterinary Echocardiography, 1998  
Abbott J & MacLean H JVIM 2006;20: 111-119, Moise et al. Am J Vet Res 47:1476, 1986. Pipers et al. Am J Vet Res 40:882, 1979.*

**INTERPRETATION OF THE FINDINGS & FURTHER RECOMMENDATIONS**

Overtly normal cardiac structure and function. Mild fibrosis of the left ventricular wall is noted, which is likely a normal age-related variant. No significant valve leaks are noted, and flow through the great vessels is normal in velocity. No definitive cause for the murmur is identified in this study, making it likely physiologic in origin (i.e. secondary to tachycardia, volume changes, etc.).



## PATIENT

Blackie Trionfetti

## SPECIES

Feline

## BREED

DSH

## SEX

Female Spayed

## AGE

9 years

## WEIGHT

12lbs

## INTERPRETED BY

Maggie Machen Lamy,  
DVM, DACVIM  
(Cardiology)

## IMAGING PERFORMED BY

Renee Trionfetti, VMD

## HOSPITAL NAME

Blue Pearl Wyomissing

## REFERRING VET

Dr. Trionfetti

## INVOICE

45629

## DATE

11/3/25

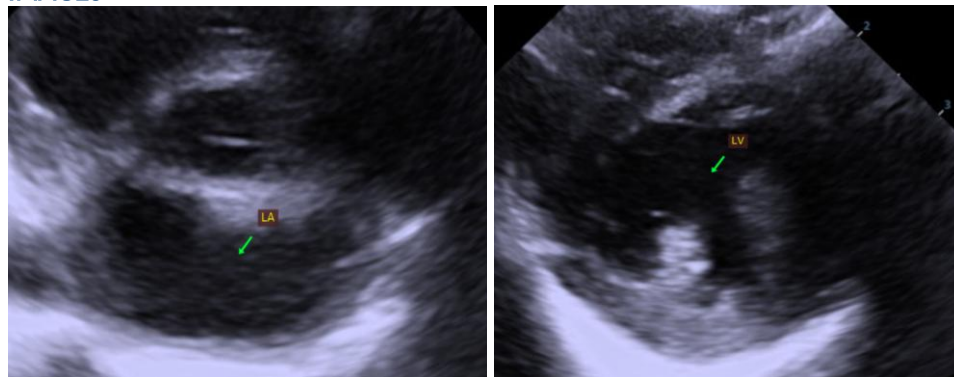
Given these findings and a normal LA dimension, no medications are indicated. Prognosis is open.

No cardiac contraindication for general anesthesia. Risk for complication with steroid or fluid use typically follows LA dilation, which in this case is low. That said, any cat can experience acute intolerance and monitoring for this phenomenon is always advised (a change in RR/RE, particularly during the initiation phase).

Monitor at home for signs of cardiac compromise, including respiratory changes and/or signs of a blood clot event (paralysis, neurologic changes).

Recommend recheck echocardiogram in 1 year to assess for any progressive issues or development of disease the pre-existing murmur may mask.

## IMAGES



The information and recommendations provided are based on the images presented by the referring veterinarian. No evaluation can be communicated regarding pathology that was not visible in the image/video clips provided.

Thank you for this referral. This report was generated using transcription software, and minor dictation errors may be present. If the clinical or image interpretation does not parallel your findings or if I can be of any further assistance, please contact me.

Maggie Machen Lamy, DVM  
Diplomate of the American College of Veterinary Internal Medicine (Cardiology)  
info@sonopath.com